

# Letters

## RESEARCH LETTER

### Presumed Asymptomatic Carrier Transmission of COVID-19

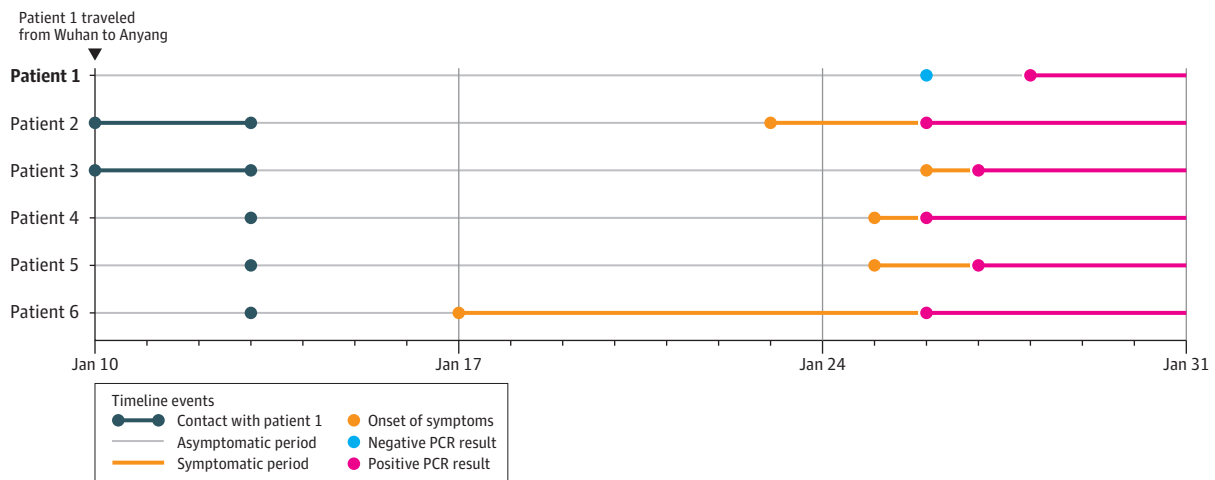
A novel coronavirus has resulted in an ongoing outbreak of viral pneumonia in China.<sup>1-3</sup> Person-to-person transmission has been demonstrated,<sup>1</sup> but, to our knowledge, transmission of the novel coronavirus that causes coronavirus disease 2019 (COVID-19) from an asymptomatic carrier with normal chest computed tomography (CT) findings has not been reported.

**Methods** | In January 2020, we enrolled a familial cluster of 5 patients with fever and respiratory symptoms who were admitted to the Fifth People's Hospital of Anyang, Anyang, China, and 1 asymptomatic family member. This study was approved by the local institutional review board, and written informed consent was obtained from all patients. A detailed analysis of patient records was performed.

All patients underwent chest CT imaging. Real-time reverse transcriptase polymerase chain reaction (RT-PCR) tests for COVID-19 nucleic acid were performed using nasopharyngeal swabs (Novel Coronavirus PCR Fluorescence Diagnostic Kit, BioGerm Medical Biotechnology).

**Results** | Patient 1 (presumed asymptomatic carrier), a 20-year-old woman, lives in Wuhan and traveled to Anyang on January 10, 2020. She initially met with patients 2 and 3 on January 10. On January 13, she accompanied 5 relatives (patients 2 through 6) to visit another hospitalized relative in Anyang District Hospital (**Figure**). There was no report of COVID-19 at this hospital. After development of disease in her relatives, patient 1 was isolated and observed. As of February 11, she had no elevated temperature measured or self-reported fever and no gastrointestinal or respiratory symptoms, including cough and sore throat, reported or observed by the physicians. Chest CT images on January 27 and 31

Figure. Timeline of Exposure to the Asymptomatic Carrier of the Novel Coronavirus That Causes COVID-19 in a Familial Cluster



PCR indicates polymerase chain reaction test for the coronavirus disease 2019 (COVID-19) nucleic acid.

Table. Summary of Laboratory Examination Results of the Familial Cluster Infected With the Novel Coronavirus That Causes Coronavirus Disease 2019

	Reference range	Patient 1 <sup>a</sup>	Patient 2	Patient 3	Patient 4	Patient 5	Patient 6
C-reactive protein, mg/L	0.0-4.0	0.69	217.17	10.14	66.07	14.9	202.03
Eosinophils, ×10 <sup>9</sup> /L	0.02-0.52	0.02	0	0.01	0	0	0
Eosinophil ratios, %	0.4-8	0.40	0	0.30	0	0.10	0
Lymphocytes, ×10 <sup>9</sup> /L	1.1-3.2	1.55	0.53	1.65	0.91	0.46	0.69
Lymphocyte ratios, %	20-50	27.50	6.70	35.90	27.70	13.30	7.40
Neutrophils, ×10 <sup>9</sup> /L	1.8-6.3	3.62	6.89	2.64	2.10	2.89	8.21
Neutrophil ratios, %	40-75	63.90	86.40	57.40	64.00	84.10	87.00
White blood cell count, ×10 <sup>9</sup> /L	3.9-9.9	5.65	7.97	4.59	3.29	3.44	9.43

<sup>a</sup> Asymptomatic.

showed no significant abnormalities. Her C-reactive protein level and lymphocyte count were normal (Table). Results of RT-PCR testing were negative on January 26, positive on January 28, and negative on February 5 and 8.

Patients 2 through 6 developed COVID-19. Four were women, and ages ranged from 42 to 57 years. None of the patients had visited Wuhan or been in contact with any other people who had traveled to Wuhan (except patient 1).

Patients 2 through 5 developed fever and respiratory symptoms between January 23 and January 26 and were admitted to the hospital on the same day. All patients had RT-PCR test results positive for COVID-19 within 1 day. Patient 6 developed fever and sore throat on January 17 and went to the local clinic for treatment. There was no report of COVID-19 at the clinic. Her symptoms improved over the next few days but worsened on January 24, when she was admitted to the hospital and confirmed to have COVID-19 on January 26. Two patients developed severe pneumonia; the other infections were moderate.

All symptomatic patients had multifocal ground-glass opacities on chest CT, and 1 also had subsegmental areas of consolidation and fibrosis. All the symptomatic patients had increased C-reactive protein levels and reduced lymphocyte counts (Table).

**Discussion** | A familial cluster of 5 patients with COVID-19 pneumonia in Anyang, China, had contact before their symptom onset with an asymptomatic family member who had traveled from the epidemic center of Wuhan. The sequence of events suggests that the coronavirus may have been transmitted by the asymptomatic carrier. The incubation period for patient 1 was 19 days, which is long but within the reported range of 0 to 24 days.<sup>4</sup> Her first RT-PCR result was negative; false-negative results have been observed related to the quality of the kit, the collected sample, or performance of the test. RT-PCR has been widely deployed in diagnostic virology and has yielded few false-positive outcomes.<sup>5</sup> Thus, her second RT-PCR result was unlikely to have been a false-positive and was used to define infection with the coronavirus that causes COVID-19.

One previous study reported an asymptomatic 10-year-old boy with COVID-19 infection, but he had abnormalities on chest CT.<sup>6</sup> If the findings in this report of presumed transmission by an asymptomatic carrier are replicated, the prevention of COVID-19 infection would prove challenging. The mechanism by which asymptomatic carriers could acquire and transmit the coronavirus that causes COVID-19 requires further study.

**Yan Bai, MD**  
**Lingsheng Yao, MD**  
**Tao Wei, MD**  
**Fei Tian, MD**  
**Dong-Yan Jin, PhD**  
**Lijuan Chen, PhD**  
**Meiyun Wang, MD, PhD**

**Author Affiliations:** Department of Medical Imaging, Henan Provincial People's Hospital, Zhengzhou, Henan, China (Bai, Chen, Wang); Department of Radiology, Anyang Hospital of Traditional Chinese Medicine, Anyang, Henan, China (Yao); Department of Radiology and Interventional, the Fifth People's Hospital of Anyang, Anyang, Henan, China (Wei); Tianjin Medical University Cancer Institute and Hospital, Tianjin, China (Tian); Li Ka Shing Faculty of Medicine, the University of Hong Kong, Pokfulam, Hong Kong, China (Jin).

**Corresponding Author:** Meiyun Wang, MD, PhD, Department of Medical Imaging, Henan Provincial People's Hospital and the People's Hospital of Zhengzhou University, No. 7, WeiWu Road, Zhengzhou 450003, Henan, China ([mywang@ha.edu.cn](mailto:mywang@ha.edu.cn)).

**Published Online:** February 21, 2020. doi:[10.1001/jama.2020.2565](https://doi.org/10.1001/jama.2020.2565)

**Author Contributions:** Drs Yao and Wang had full access to all of the data in the study and take responsibility for the integrity of the data and the accuracy of the data analysis. Drs Bai, Yao, and Wei contributed equally to the work.

**Concept and design:** Bai, Yao, Tian, Jin, Wang.

**Acquisition, analysis, or interpretation of data:** Bai, Yao, Wei, Tian, Chen, Wang.

**Drafting of the manuscript:** Bai, Yao, Wei, Tian, Wang.

**Critical revision of the manuscript for important intellectual content:** Bai, Tian, Jin, Chen, Wang.

**Statistical analysis:** Bai, Chen, Wang.

**Administrative, technical, or material support:** Bai, Yao, Wei, Tian, Wang.

**Supervision:** Tian, Wang.

**Conflict of Interest Disclosures:** None reported.

**Additional Contributions:** We thank Taiyuan Liu, MD, Rushi Chen, MD, and Wei Wei, MD (Henan Provincial People's Hospital and the People's Hospital of Zhengzhou University), for data analysis and literature research. None of these persons received any compensation for their contributions.

1. Paules CI, Marston HD, Fauci AS. Coronavirus infections—more than just the common cold. *JAMA*. Published online January 23, 2020. doi:[10.1001/jama.2020.0757](https://doi.org/10.1001/jama.2020.0757)
2. Li Q, Guan X, Wu P, et al. Early transmission dynamics in Wuhan, China, of novel coronavirus-infected pneumonia. *N Engl J Med*. Published online January 29, 2020. doi:[10.1056/NEJMoa2001316](https://doi.org/10.1056/NEJMoa2001316)
3. Wang D, Hu B, Hu C, et al. Clinical characteristics of 138 hospitalized patients with 2019 novel coronavirus-infected pneumonia in Wuhan, China. *JAMA*. Published online February 7, 2020. doi:[10.1001/jama.2020.1585](https://doi.org/10.1001/jama.2020.1585)
4. Guan WJ, Ni ZY, Hu Y, et al. Clinical characteristics of 2019 novel coronavirus infection in China. medRxiv. Published February 9, 2020. Accessed February 18, 2020. <https://www.medrxiv.org/content/10.1101/2020.02.06.20020974v1>
5. Corman VM, Landt O, Kaiser M, et al. Detection of 2019 novel coronavirus (2019-nCoV) by real-time RT-PCR. *Euro Surveill*. Published online January 23, 2020. doi:[10.2807/1560-7917.ES.2020.25.3.2000045](https://doi.org/10.2807/1560-7917.ES.2020.25.3.2000045)
6. Chan JF, Yuan S, Kok KH, et al. A familial cluster of pneumonia associated with the 2019 novel coronavirus indicating person-to-person transmission: a study of a family cluster. *Lancet*. 2020;395(10223):514-523. doi:[10.1016/S0140-6736\(20\)30154-9](https://doi.org/10.1016/S0140-6736(20)30154-9)